

**Сведения о животном**

**Pet Information**

имя name	TRAMIN Milk And Honey	владелец owner	Ushan E
порода breed	golden retriever	микрочип microchip	900085000167567
пол sex	female	тату tattoo	—
дата рождения date of birth	16.09.2019	родословная pedigree	

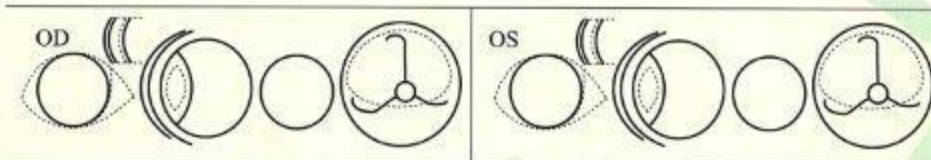
**Заключение о состоянии глаз собаки**  
 Certificate of eye examination

« 5 » 03 2020

Conclusion is valid for 12 months

**Methods**

- direct ophthalmoscope     funduscamera  
 indirect ophthalmoscope     tonometry  
 gonioscope     others



	palpebrae	eye ball	cornea	iris	lens	vitreo	fundus
normal	<input checked="" type="checkbox"/>	<input checked="" type="checkbox"/>	<input checked="" type="checkbox"/>	<input checked="" type="checkbox"/>	<input checked="" type="checkbox"/>	<input checked="" type="checkbox"/>	<input checked="" type="checkbox"/>
pathology	<input type="checkbox"/>	<input type="checkbox"/>	<input type="checkbox"/>	<input type="checkbox"/>	<input type="checkbox"/>	<input type="checkbox"/>	<input type="checkbox"/>
tests	<input type="checkbox"/>	<input type="checkbox"/>	<input type="checkbox"/>	<input type="checkbox"/>	<input type="checkbox"/>	<input type="checkbox"/>	<input type="checkbox"/>

**Conclusion**

Animal is

health

unproved health

not health

**Clinical signs of ophthalmic pathology:**

normal		unproved	pathology
<input checked="" type="checkbox"/>	mycrophthalm	<input type="checkbox"/>	<input type="checkbox"/>
<input checked="" type="checkbox"/>	palpebrae's aplasia (coloboma)	<input type="checkbox"/>	<input type="checkbox"/>
<input checked="" type="checkbox"/>	atrezia lacrimal punctum	<input type="checkbox"/>	<input type="checkbox"/>
<input checked="" type="checkbox"/>	pupilar membrana (perseverens)	<input type="checkbox"/>	<input type="checkbox"/>
<input checked="" type="checkbox"/>	glaucoma	<input type="checkbox"/>	<input type="checkbox"/>
<input checked="" type="checkbox"/>	entropion	<input type="checkbox"/>	<input type="checkbox"/>
<input checked="" type="checkbox"/>	ectropion	<input type="checkbox"/>	<input type="checkbox"/>

normal		unproved	pathology
<input checked="" type="checkbox"/>	trichiasis	<input type="checkbox"/>	<input type="checkbox"/>
<input checked="" type="checkbox"/>	districhiasis	<input type="checkbox"/>	<input type="checkbox"/>
<input checked="" type="checkbox"/>	corneal dystrophy	<input type="checkbox"/>	<input type="checkbox"/>
<input checked="" type="checkbox"/>	cataracta	<input type="checkbox"/>	<input type="checkbox"/>
<input checked="" type="checkbox"/>	lens luxation	<input type="checkbox"/>	<input type="checkbox"/>
<input checked="" type="checkbox"/>	pigment retinal atrophy	<input type="checkbox"/>	<input type="checkbox"/>
<input checked="" type="checkbox"/>	retinal detachment	<input type="checkbox"/>	<input type="checkbox"/>
<input checked="" type="checkbox"/>	nervus opticus atrophy	<input type="checkbox"/>	<input type="checkbox"/>

PHd, MD ophthalmology

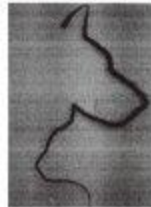ВЕТЕРИНАРНА КЛІНІКА  
 Т. 7601279 "ВЕЛЕС"  
 ОДЕСА, ЛЕВАНЕВСЬКОГО 5  
 ФОРТ ОДЕСА ІНД. ПП

Dina Tereschenko

# "VELES"

Name: Ushan ,Elena    Animal: Dog  
Host: Tramin Milk And Honey  
ID: 20200203-143824-E8DA  
No.: 900085000167567...  
DOB: 16/09/2019    Age: 5Months  
Gender: Female

Odessa, Levanevskogo str.5  
Telephone: +380487601279  
Fax:  
Website:



## Cardiac2

Exam Date: 03/02/2020

Equipment Used: MINDRAY Z6Vzt

Ветеринарна лікарня

VELES

"Велес"

тел. +38 (048) 760 12 79

e-mail: zooveles@yandex.ua

## Cardiology-Page 1

### 2D Measurements

#### Dimensions

##### LA/Ao(2D)

LA Diam: 2.37cm

Ao Diam: 1.91cm

LA/Ao: 1.24

MPA Diam: 1.51cm

### M Measurements

#### Dimensions

RVDd: 1.07cm

#### Ventricle Volume

##### Teichholz(M)

IVSd: 0.68cm

LVIDd: 3.32cm

LVPWd: 0.63cm

IVSs: 1.07cm

LVIDs: 2.00cm

LVPWs: 1.51cm

EDV(Teich): 44.83ml

ESV(Teich): 12.77ml

SV(Teich): 32.06ml

EF(Teich): 71.51%

FS(Teich): 39.71%

### Doppler Measurements

#### Mitral Valve



Name: Ushan ,Elena Animal: Dog Host: Tramin Milk And Honey  
 ID: 20200203-143824-E8DA No.: 900085000167567 DOB: 16/09/2019 Age: 5Months  
 Gender: Female  
**Cardiac2**  
 Exam Date: 03/02/2020

Animal Health Center  
 Ветеринарна лікарня  
 VELES  
 "Велес"  
 тел. +38 (048) 760 12 79  
 e-mail: zooveles@yandex.ua

**Cardiology-Page 2**

MV E Vel: 77.27cm/s

MV E PG: 2.39mmHg

MV A Vel: 52.95cm/s

MV A PG: 1.12mmHg

MV E/A: 1.46

IVRT: 0.052s

Aortic

AV Vmax: 113.05cm/s

AV PGmax: 5.11mmHg

Tricuspid Valve

TV Vmax: 70.12cm/s

TV PGmax: 1.97mmHg

Pulmonary Artery

MPA Vmax: 103.03cm/s

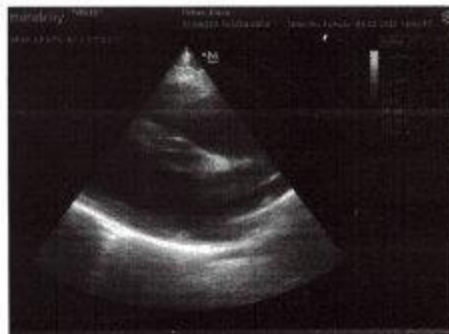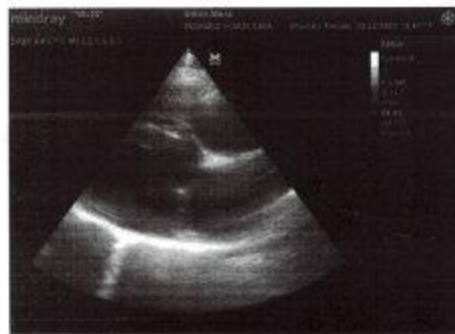MPA PGmax: 4.25mmHg

TDI Measurements

MV E/A

MV E Vel: 77.27cm/s

Ultrasound Image

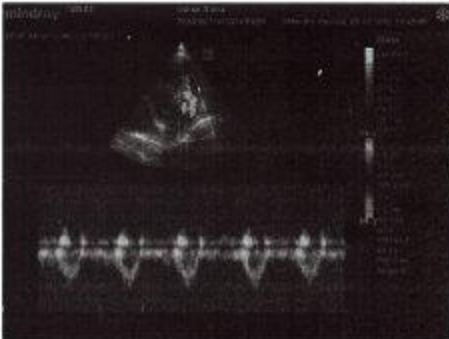
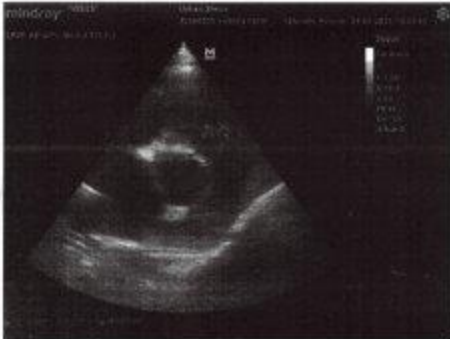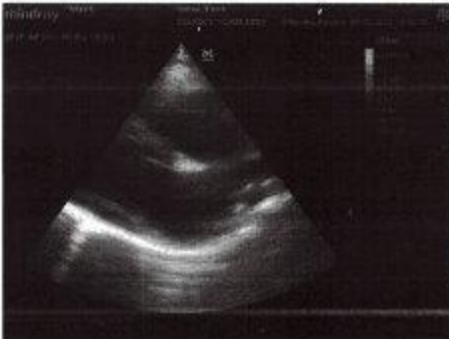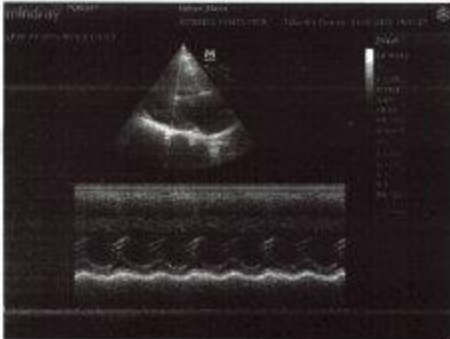




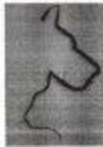Name: Ushan, Elena    Animal: Dog    Host: Tramin Milk And Honey  
ID: 20200203-143824-E8DA    No.: 900085000167567    DOB: 16/09/2019    Age: 5 Months  
Gender: Female  
**Cardiac2**  
Exam Date: 03/02/2020

 **Animal Health Center**  
Ветеринарна лікарня  
VULES  
"Вулес"  
тел. +38 (048) 760 12 79  
e-mail: zooveles@yandex.ua

**Cardiology-Page 3**





Name: Ushan, Elena Animal: Dog Host: Tramin Milk And Honey  
ID: 20200203-143824-E8DA No.: 900085000167567 DOB: 16/09/2019 Age: 5Months  
Gender: Female  
**Cardiac2**  
Exam Date: 03/02/2020

**Cardiology-Page 4**

**Comments:**

The cavity of the left ventricle is not extended.  
Mitral valve: not changed. Regurgitation: none.  
Diastolic function of the myocardium of the left ventricle is not broken.  
Violation of local contractility of the left ventricle: no.  
Aortic valve: the leaf is not sealed. The amplitude disclosure: normal.  
Regurgitation: none. Aorta: 19,1mm, Left atrium: 23,7 mm.  
IVS: not thickened; Posterior wall LV: not thickened.  
The cavity of the right ventricle is not extended. Tricuspid valve: not changed.  
Regurgitation: non.  
Valve LA: not changed. Regurgitation: non. Pulmonary artery: not expanded.  
Dopplerechocardiography: pathological threads  
VSD: no. ASD: no.  
Pericardial fluid: no.  
**Conclusion:** Heart shaped correctly. The valve apparatus is not changed. Violations of general and intracardiac hemodynamics is not revealed.

Signature(seal):

Date Signed:

Animal Health Center  
Ветеринарна лікарня  
VELES  
"Велес"  
тел +38 (048) 760 12 79  
e-mail: zooveles@yandex.ua

Сведения о животном

Pet Information

имя name	Трамін Milk and Honey	владелец owner	Ughan B
порода breed	golden retriever	микрочип microchip	300085000167567
пол sex	female	тату tattoo	—
дата рождения date of birth	5. 03. 2020	родословная pedigree	

Заключение о состоянии тазобедренных суставов собаки

Hips dysplasia description

	левый left	правый right
1 Угол Норберга Norberg angle	115°	112°
2 Индекс внедрения головки бедра во впадину Index of introduction of the femoral head into the acetabulum	<input checked="" type="checkbox"/> ≥50% <input checked="" type="checkbox"/> ≤50%	<input checked="" type="checkbox"/> ≥50% <input type="checkbox"/> ≤50%
3 Форма передненаружного края вертлужной впадины The shape of the anterior outer edge of the acetabulum	<input checked="" type="checkbox"/> острый / sharp <input type="checkbox"/> закругленный / rounded	<input checked="" type="checkbox"/> острый / sharp <input type="checkbox"/> закругленный / rounded
4 Тангенциальный угол Tangential angle	<input checked="" type="checkbox"/> отрицательный / negative <input type="checkbox"/> горизонтальный / horizontal <input type="checkbox"/> положительный / positive	<input checked="" type="checkbox"/> отрицательный / negative <input type="checkbox"/> горизонтальный / horizontal <input type="checkbox"/> положительный / positive
5 Состояние замыкательной пластины свода вертлужной впадины Condition of endplate vault of the acetabulum	<input checked="" type="checkbox"/> норма / norm <input type="checkbox"/> равномерно утолщена / uniformly thickened <input type="checkbox"/> медиально редуцирована / medially reduced	<input checked="" type="checkbox"/> норма / norm <input type="checkbox"/> равномерно утолщена / uniformly thickened <input type="checkbox"/> медиально редуцирована / medially reduced
6 Головка бедра The femoral head	<input type="checkbox"/> круглая / round <input type="checkbox"/> грибовидная / mushroom-shaped <input type="checkbox"/> угловатая / angulate <input type="checkbox"/> уплощенная / flatten	<input type="checkbox"/> круглая / round <input type="checkbox"/> грибовидная / mushroom-shaped <input type="checkbox"/> угловатая / angulate <input type="checkbox"/> уплощенная / flatten
7 Экзостозы на шейке бедра Femoral neck exostosis	<input checked="" type="checkbox"/> нет / no <input type="checkbox"/> да / yes	<input checked="" type="checkbox"/> нет / no <input type="checkbox"/> да / yes
Вывод Conclusion	HD (A) B C D E	(A) B C D E

Заключение о состоянии локтевых суставов собаки

Elbow dysplasia description

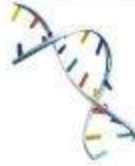	левый left	правый right
1 Наличие остеофитов The presence of osteophytes	<input checked="" type="checkbox"/> нет / no <input type="checkbox"/> 2-5 мм / 2-5 mm <input type="checkbox"/> > 5 мм / > 5 mm	<input checked="" type="checkbox"/> нет / no <input type="checkbox"/> 2-5 мм / 2-5 mm <input type="checkbox"/> > 5 мм / > 5 mm
2 Ступенька между локтевой и лучевой костями Step between the ulna and radius bones	<input checked="" type="checkbox"/> отсутствует / not present <input type="checkbox"/> < 2 мм / < 2 mm <input type="checkbox"/> 2-5 мм / 2-5 mm <input type="checkbox"/> > 5 мм / > 5 mm	<input checked="" type="checkbox"/> отсутствует / not present <input type="checkbox"/> < 2 мм / < 2 mm <input type="checkbox"/> 2-5 мм / 2-5 mm <input type="checkbox"/> > 5 мм / > 5 mm
3 Трабекулярный контур The trabecular contour	<input checked="" type="checkbox"/> четко виден / clearly visible <input type="checkbox"/> просматривается / slightly visible <input type="checkbox"/> не виден / not visible	<input checked="" type="checkbox"/> четко виден / clearly visible <input type="checkbox"/> просматривается / slightly visible <input type="checkbox"/> не виден / not visible
4 Признаки первичного поражения сустава Signs of primary joint disease (FCP, OCD, UAP)	<input checked="" type="checkbox"/> нет / no <input type="checkbox"/> да / yes	<input checked="" type="checkbox"/> нет / no <input type="checkbox"/> да / yes
Вывод Conclusion	ED (0) 1 2 3	(0) 1 2 3

« 6 » 03 20 20

ВЕТЕРИНАРНАЯ КЛИНИКА  
Т. 7601279 "ВЕЛЕС"

Roman Oleksenko  
Director of Animal health center V.D.


# Canine Genetic Testing Report



**Submitted By**  
 Jesse Zehr  
 Dutch Central Stables  
 14425 Antwerp Rd  
 Grabbill, IN 46741

**Subject Dog** #0357210 Date Received: 3/26/2022  
 Dog Name: **Tramin Milk and Honey** Registration: SS21332501  
 Breed: Golden Retriever Microchip: 9000085000167567  
 Phenotype: Light Golden Sex: Female Birth: 09/16/2019

Sire	Dam																																										
Sire Name: Breed: Registration: Phenotype:	Dam Name: Breed: Registration: Phenotype:																																										
Coat Color Testing																																											
A Locus-Ay	Genetic Disorders																																										
A Locus-Aw	<b>X</b> DM <span style="color: orange;">n/n</span> Clear: Dog is negative for the SOD1A Degenerative Myelopathy mutation.																																										
A Locus-At	<b>X</b> GR-PRA1 <span style="color: orange;">n/n</span> Clear: Dog tested negative for the GR-PRA1 mutation.																																										
A Locus-a	<b>X</b> GR-PRA2 <span style="color: orange;">n/n</span> Clear: Dog tested negative for the GR-PRA2 mutation.																																										
B Locus	<b>X</b> Ich <span style="color: orange;">n/n</span> Clear: Dog tested negative for the Ichthyosis mutation.																																										
Cocoon	<b>X</b> MD <span style="color: orange;">n/n</span> Clear: Dog tested negative for the Marfan/Dystrophy mutation.																																										
D Locus	MI																																										
E Locus-EM	<b>X</b> NCL-GR <span style="color: orange;">n/n</span> Clear: Dog tested negative for the NCL mutation.																																										
E Locus-e	<b>X</b> prod-PRA <span style="color: orange;">n/n</span> Clear: Dog is negative for the causal prod-PRA c.5G>A mutation.																																										
K Locus-KB																																											
Spotting	<b>Genetic Marker Results</b> <span style="float: right;">Run Date: 3/26/2022</span>																																										
Harlequin	<table border="1" style="width: 100%; text-align: center;"> <tr> <td>-</td><td>-</td><td>-</td><td>-</td><td>-</td><td>-</td><td>-</td> </tr> <tr> <td>AH121</td><td>AH137</td><td>AH1371</td><td>AH1269</td><td>AH1211</td><td>AH1210</td><td>C22-179</td> </tr> <tr> <td>-</td><td>-</td><td>-</td><td>-</td><td>-</td><td>-</td><td>-</td> </tr> <tr> <td>CA1-AM1</td><td>FH1014</td><td>FH1015</td><td>INEA1</td><td>IN1005</td><td>IN1011</td><td>IN1013</td> </tr> <tr> <td>-</td><td>-</td><td>-</td><td>-</td><td>-</td><td>-</td><td>-</td> </tr> <tr> <td>REN1011</td><td>REN1014</td><td>REN1001</td><td>REN1001L</td><td>REN1003</td><td></td><td></td> </tr> </table>	-	-	-	-	-	-	-	AH121	AH137	AH1371	AH1269	AH1211	AH1210	C22-179	-	-	-	-	-	-	-	CA1-AM1	FH1014	FH1015	INEA1	IN1005	IN1011	IN1013	-	-	-	-	-	-	-	REN1011	REN1014	REN1001	REN1001L	REN1003		
-	-	-	-	-	-	-																																					
AH121	AH137	AH1371	AH1269	AH1211	AH1210	C22-179																																					
-	-	-	-	-	-	-																																					
CA1-AM1	FH1014	FH1015	INEA1	IN1005	IN1011	IN1013																																					
-	-	-	-	-	-	-																																					
REN1011	REN1014	REN1001	REN1001L	REN1003																																							
Merle	<b>Additional Comments</b>																																										
Coat Type Testing																																											
Hair Length																																											
Hair Curl																																											
Furnishings																																											
Shedding																																											

e-mail: [hotline@uku.com.ua](mailto:hotline@uku.com.ua)  **UKRAINIAN KENNEL UNION**  **CERTIFIED PEDIGREE** <http://www.uku.com>

**EXPORT PEDIGREE**

Name / Ім'я: **TRAMIN MILK AND HONEY** No Pedigree / № Подорожжя: **UKU.0439833** Mark / ґрафік Чип / ґіт: **900085000167567**

Breed / Порода: **GOLDEN RETRIEVER** Sex / Стать: **FEMALE** Date of birth / Дата народження: **16.09.2019** Color / Колір: **GOLD** Kennel Name / Назва: **TRAMIN**

Breeder / Вирощувач: **USHAN OLENA** Address / Адреса: **HORIKHOVA N23 ODESA, UKRAINE 65038** Owner / Власник: **DANIEL YODER** Address / Адреса: **10510 E 350th AVE FLAT ROCK, IL 62427, USA**

**1 Sire / батько**

- GOLDENRUSH GOOD LIFE RKF 4613802, UKU 0324120, GOLD C.I.E., JCH UA, R, BG, JGRCH UA, CH CG, HD-A, ED-0/0, PCR(GR, PRA1, GR, PRA2, pros-PRA, ICT, MD)-clear BOBx4, BOSx2, CACx8, CACIBx6, R, CACx2, R, CACIBx2, USHAN OLENA
- NON-STOP PINK FLOYD MET Gold r. 5014, RKF 4094426, GOLD JCH RUS, CH RUS, HD-A, ED-0
- JUNONA GLORY OF THE SUN RKF 3493469, GOLD JCH RUS, CH RUS, RKF, HD-A, ED-0

**2 Dam / мати**

- TRAMIN SPIRIT OF LOVE UKU 0295459, GOLD HD-A, ED-0/0, PCR(GR, PRA1, GR, PRA2)-clear CACx2, USHAN OLENA
- VESTAFJELL'S MAGIC ELF NKK 3023314, LOE 2194398, GOLD C.I.E. Eyes-clear, PRA 1/2, CT-clear, HD-A, ED-0
- TRAMIN NEW MELODY UKU 0157052, GOLD CACx1

**3** GOLD FASHION KEEP THE FAITH S 437202009, GOLD HD-A, ED-0

**8** ISADORABLE V D. BEERSE HOEVE MET Gold r. 69111, GOLD HD-A, ED-0

**9** ARAGON IZ DOLINY SOLINCA RKF 2433715, GOLD C.I.B., JCH RUS, UA, BIR, CH RUS, UA, R, SB, BG, MAC, GE, MOL, CG, RKF, BIR, LIT, CW, FT-DUCK, HD-A, ED-0


**10** TRAMIN OLIVIA STAR SKY RKF 2924417, UKU 0063108, GOLD JCH RUS, CH RUS, HD-B, ED-0


**11** JAKO'S NORDIC CHARM NKK 0894904, GOLD CH N, SE, Win N, SE TCH SE, HD-A, ED-0

**12** FENWOOD ELLES BELLES KC AM04773404, GOLD CH N, SE, Win N, Win NORD, EW

**13** REMINGTON RINGMASTER KC AC03426606, LOF 8 RET, GOL 05270507096, LOE 2092354, GOLD HD-A, Eyes-clear

**14** TRAMIN PRIMA MELODY UKU 0077133, GOLD HD-A

 R. Shimerkna Natalia *свідоцтвається за Підписом юрної КСЧ, зобов'язую, що всі надані дані є достовірними*  
the guardian of the Ukrainian dog stud book, certify that here above information is correct and reliable

29.07.2020  230447

**AMERICAN KENNEL CLUB**

NAME: **TRAMIN MILK AND HONEY (AKC DNA #V941636) (UKRAINE)** NUMBER: **SS21332501**

BREED: **GOLDEN RETRIEVER** SEX: **FEMALE**


COLOR: **GOLDEN** DATE OF BIRTH: **SEPTEMBER 16, 2019**

SIRE: **GOLDENRUSH GOOD LIFE UKU 0324120 06-18 (RUS)**

DAM: **TRAMIN SPIRIT OF LOVE UKU 0295459**

BREEDER: **OLENA USHAN**

OWNER: **JESSE ZEHER 14425 ANTWERP RD GRABILL IN 46741-9778**

 **AMERICAN KENNEL CLUB®**

CERTIFICATE ISSUED **MARCH 3, 2022**

*This certificate invalidates all previous certificates issued.*

*If a date appears after the name and number of the sire and dam, it indicates the issue of the Stud Book Register in which the sire or dam is published.*

**For Transfer Instructions, see back of Certificate.**

*This Certificate issued with the right to correct or revoke by the American Kennel Club.*

**REGISTRATION CERTIFICATE**