



Belarus, Vitebsk, Chkalova street 68
Dr. Bazylevsky A. A. Veterinary Center
+375 29 319-61-19, +375 33 319-61-19
www.bazylevsky-vet.com

CERTIFICATE OF EYE EXAMINATION

Pet name SKY PRIDE PASKAL Studbook No. BCU 111-002933
Breed golden retriever Colour cream Date of birth 14.02.2022 Sex: M F
Previous examination No Yes Date of last examination _____ Microchip/tattoo No 900215002717643
Owner's name Petrovskaya A.N.
Owner's address ul. Molodezhnaya 105-8, Novopolotsk, Belarus Owner's telephone number _____

I hereby declare that the dog submitted for examination is the one described above. I agree that the registration document should be stamped with the date of this examination and that the information obtained may be available for research purposes and may be published (deletion of these statements invalidates the certificate).

16.12.2022
Date

Owner's signature

EXAMINATION OF EYE AND ADNEXA

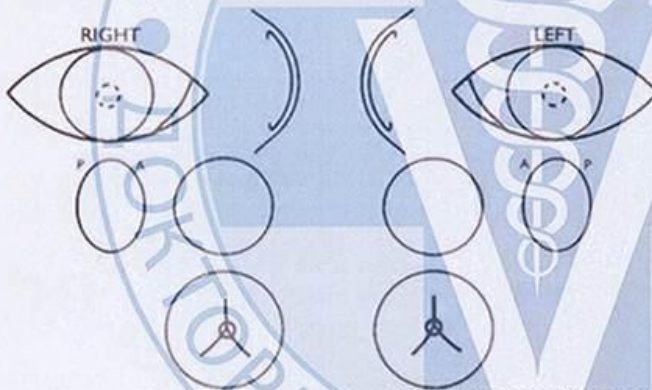
Mydriatic Ophthalmoscopy: Direct Indirect Biomicroscopy Other _____

Parts examined: Adnexa Cornea Iris Lens Vitreous Fundus
Clinically unaffected
Clinically affected _____

Descriptive comments

Next examination _____

16.12.2023



INHERITED EYE DISEASE STATUS

CONGENITAL	Unaffected	Affected	NON-CONGENITAL	Unaffected	Affected
CEA Collie eye anomaly - horoidal hypoplasia - coloboma	<input checked="" type="checkbox"/>	<input type="checkbox"/>	GPRA Generalised progressive retinal atrophy	<input checked="" type="checkbox"/>	<input type="checkbox"/>
MRD Multifocal retinal dysplasia	<input checked="" type="checkbox"/>	<input type="checkbox"/>	CPRA Central progressive retinal atrophy	<input checked="" type="checkbox"/>	<input type="checkbox"/>
TRD Total retinal dysplasia	<input checked="" type="checkbox"/>	<input type="checkbox"/>	HC Hereditary cataract	<input checked="" type="checkbox"/>	<input type="checkbox"/>
CHC Congenital hereditary cataract	<input checked="" type="checkbox"/>	<input type="checkbox"/>	PŁL Primary lens luxation	<input checked="" type="checkbox"/>	<input type="checkbox"/>
PHPV Persistent hyperplastic primary vitreous	<input checked="" type="checkbox"/>	<input type="checkbox"/>	The age of onset of non-congenital inherited eye disease varies in different breeds and between individual dogs. It is therefore important to follow any advice given at the time of this examination with regard to the necessity for frequency of eye examination		
PPM Persistent pupillary membrane	<input checked="" type="checkbox"/>	<input type="checkbox"/>			
G Goniodysgenesis	<input checked="" type="checkbox"/>	<input type="checkbox"/>	I confirm that the scanned microchip/tattoo number matches the number on this certificate <input checked="" type="checkbox"/>		

I have examined the above animal today with the results as shown

Signature



A. BAZYLEVSKY
Veterinary doctor

16.12.2022
Date



Belarus, Vitebsk, Chkalova street 68
Dr. Bazylevsky A. A. Veterinary Center
+375 29 319-61-19, +375 33 319-61-19
www.bazylevskyvet.com

HIP-/ELBOW DYSPLASIA INTERNATIONAL CERTIFICATE

X-Rays made on: 16.12.2022

Breed: golden retriever

Name: SKY PRIDE PASKAL

Sex: Female
 Male

Birth date: 14.02.2022

Studbook: BCU

Registration № 111-002933

Tattoo/chip №: 900215002717643

Owner: Petrovskaya A.N.

Address: ul. Molodezhnaya 105-8, Vitebskaya obl, Novopolotsk

Classification: (circle the relevant)

HIP Right	<input checked="" type="radio"/> A	<input type="radio"/> B	<input type="radio"/> C	<input type="radio"/> D	<input type="radio"/> E
HIP Left	<input checked="" type="radio"/> A	<input type="radio"/> B	<input type="radio"/> C	<input type="radio"/> D	<input type="radio"/> E
Elbow Right	<input checked="" type="radio"/> 0	<input type="radio"/> 1	<input type="radio"/> 2	<input type="radio"/> 3	
Elbow Left	<input checked="" type="radio"/> 0	<input type="radio"/> 1	<input type="radio"/> 2	<input type="radio"/> 3	

The evaluation was made by: Alexey Bazylevsky,
DVM, HD/ED expert of Belarusian Cynological Society (F.C.I.)

The procedure has been performed according to the rules of F.C.I.

Signature 

Stamp



Dr. A. Bazylevsky



Belarus, Vitebsk, Chkalova street 68
Dr. Bazylevsky A.A. Veterinary Center
+375 33 319-61-19, +375 29 319-
6119www.bazylevsky-vet.com

CERTIFICATE OF ECHOCARDIOGRAPHY EXAMINATION

Nr. 179/3964 Date: 16.12.2022

Animal name SKY PRIDE PASKAL Reg. Animal name SKY PRIDE PASKAL
 Breed golden retriever Color cream Date of birth 14.02.2022
 Microchip/tattoo No 900215002717643 Studbook # BCU 111-002933 Weight 32 kg Sex M F
 Owner's name Petrovskaya A.N. Owner's telephone number _____
 Owner's address ul. Molodezhnaya 105-8, Novopolotsk

I hereby declare that the dog submitted for examination is the one described above. Further, I understand that this certificate is not guarantee of clearance from congenital heart disease, but rather the results of today's cardiac examination. I accept that the results of examination are public and the information obtained may be available for research purposes and utilized by the breed association(s) concerned.

16.12.2022
date

owner's signature

	Aortic stenosis	Pulmonic stenosis
free	0	0
trivial	1	1
mild	2	2
moderate	3	3
severe	4	4
subvalv.		
valv.		

	VSD	ASD
MD		TD
PDA		TT

2D-Mode:
 Dia. Ao expected: 1,86 cm
 Area Ao expected: 2,72 cm
 Dia. Ao at the level of the fibrous ring: 1,76 cm
 Dia. Ao at the level of the sinus of Valsalva: 1,91 cm
 RVOT above Ao valve: 1,81 cm
 RVOT above PH: 1,80 cm
 Dia. PH: 1,82 cm
 Area PH: 4,4 cm
 RVOT under pulmonary valve: 1,81 cm
 EDD LV transverse: 3,51 cm
 IS LV: 0,7
 Dia. MV: 2,40 cm
 Area MV: 4,52 cm
 Ar. MV/Ar. Ao: 1,88
 EDD RV transverse: 1,6 cm
 Dia. TV: 1,81 cm
 Area TV: 2,57 cm
 Ar. TV/Ar. MV: 0,58

Dopler:
Aortic:
 Character stream: Lam.V Turb.0
 Flow rate: 110 cm/sec
 Changes: no V yes0
Pulmonic:
 Character stream: Lam.V Turb.0
 Flow rate: 96 cm/sec
 Changes: no V yes0
Mitral:
 Character stream: Lam.V Turb.0
 Flow rate: 98 cm/sec
 Changes: no V yes0
Tricuspid:
 Character stream: Lam.V Turb.0
 Flow rate: 72 cm/sec
 Changes: no V yes0

Color flow mapping:
 MR: no V yes0
 TR: no V yes0
 AR: no V yes0
 PR: no V yes0

Valvular disease:	none	Mild	Severe
DVD mitralis	Tricuspidalis	Moder.	Severe
DVD mitralis	Tricuspidalis	Severe	
AI	PI	PHI	

Other findings:	V	0
None or minimal cardiovascular changes		0
Mild cardiovascular changes		1
Moderate cardiovascular changes		2
Severe cardiovascular changes		3

Identity checked V

16.12.2022
date

Signature and stamp of examiner
Dr. A. Bazylevsky



СОЮЗ ОБЩЕСТВЕННЫХ ОБЪЕДИНЕНИЙ • БЕЛАРУСЬСКОЕ КИНОЛОГИЧЕСКОЕ ОБЪЕДИНЕНИЕ
UNION OF PUBLIC ORGANIZATIONS • BELORUSSIAN CYNOLOGICAL UNION



Юниор
ЧЕМПИОН БЕЛАРУСИ

BELARUS JUNIOR CHAMPION

Кличка / Name **SKY PRIDE PASKAL**
 Порода / Breed **ЗОЛОТИСТЫЙ РЕТРИВЕР
GOLDEN RETRIEVER**
 Рег. № / Reg. No **BCU 111-002933**
 Владелец / Owner _____
 Дата / Date **23.12.2022**





Genetic Testing Report

Sky Pride Paskal

Submitted By

Jesse Zehr
Dutch Central Stables

Subject Dog

Dog Name: **Sky Pride Paskal**
Breed: **Golden Retriever**
Phenotype:
Sex: **Male**
Birth: **Feb 14, 2022**

Lab Reference #: **737211**
Microchip: **900215002717643**

Disorder Results (8 of 8)

DM	n/n	Clear: Dog is negative for mutation associated with Degenerative Myelopathy.
GPRA1	n/n	Clear: Dog is negative for the mutation associated with GR-PRA1.
GPRA2	n/n	Clear: Dog is negative for the mutation associated with GR-PRA2.
Ich (GR)	n/n	Clear: Dog is negative for the mutation associated with Ichthyosis.
Ich-2	n/n	Dog is clear of the mutation associated with Ichthyosis 2.
GRMD	n/n	Clear: Dog is negative for the mutation associated with Muscular Dystrophy.
NCL-GR	n/n	Clear: Dog is negative for mutation associated with NCL-GR.
PRA-prcd	n/n	Negative: Dog is negative for the mutation associated with prcd-PRA.